

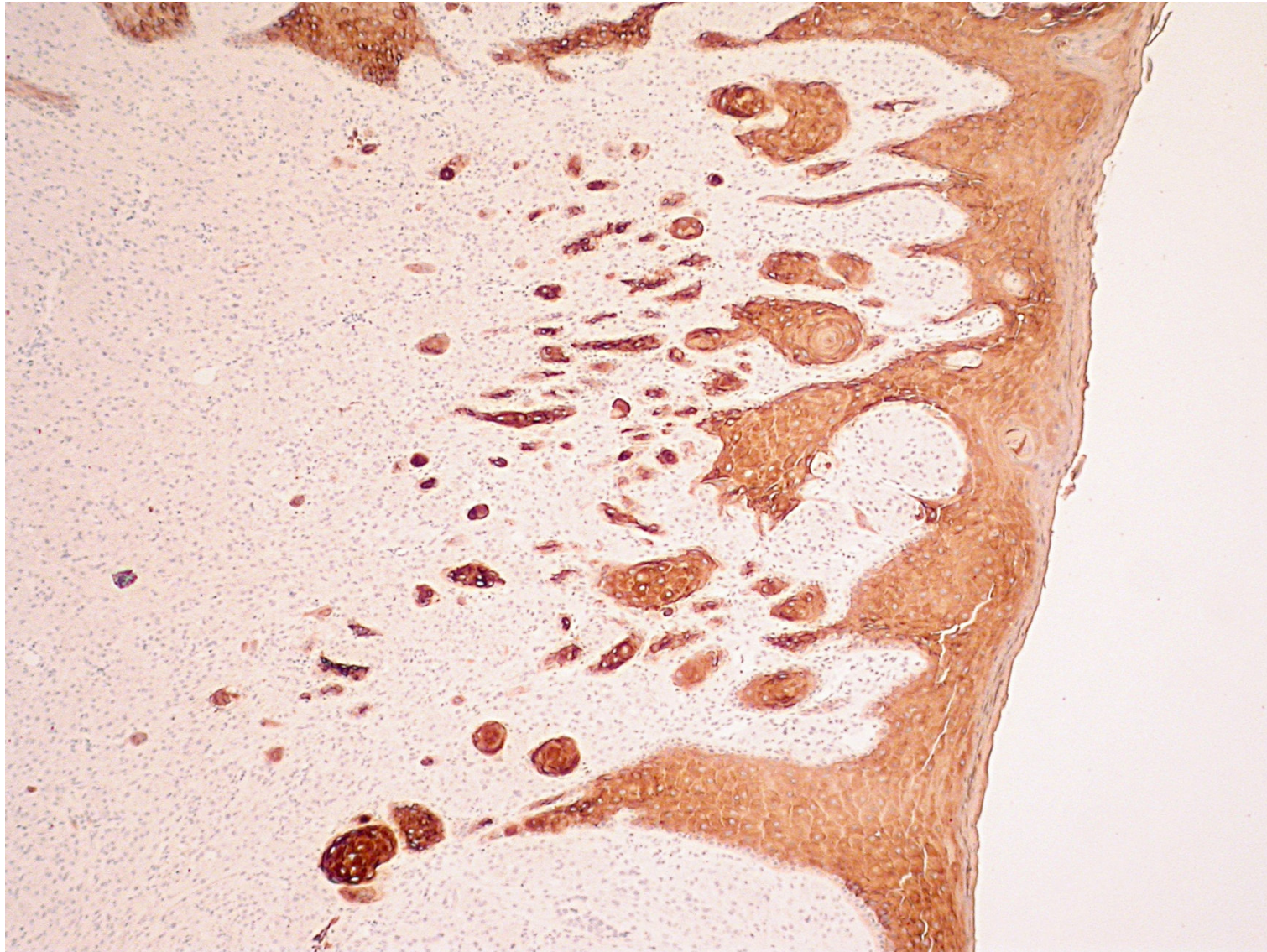
Slide Seminar

Oral Pathology

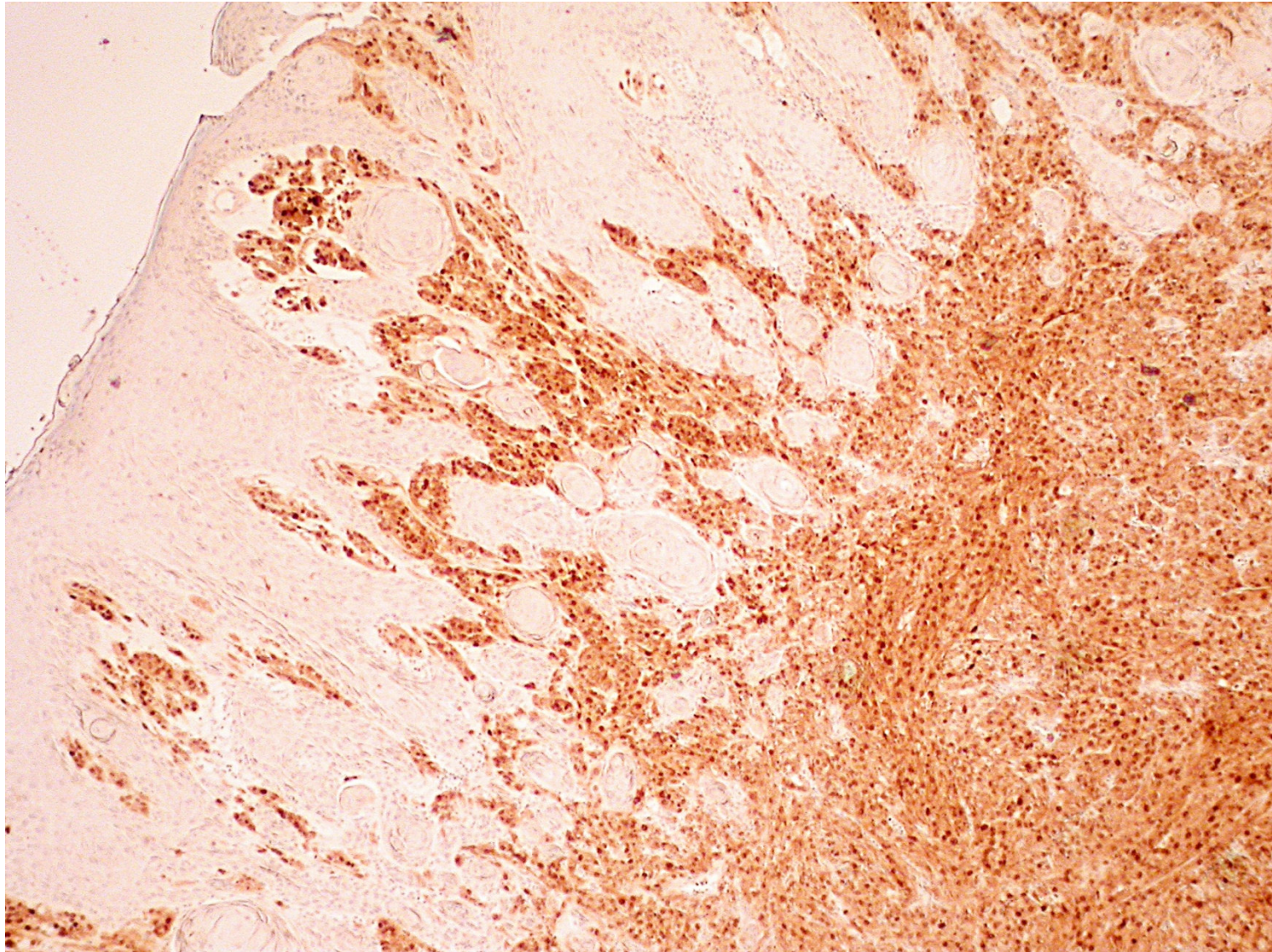
Case 6

Female 50y

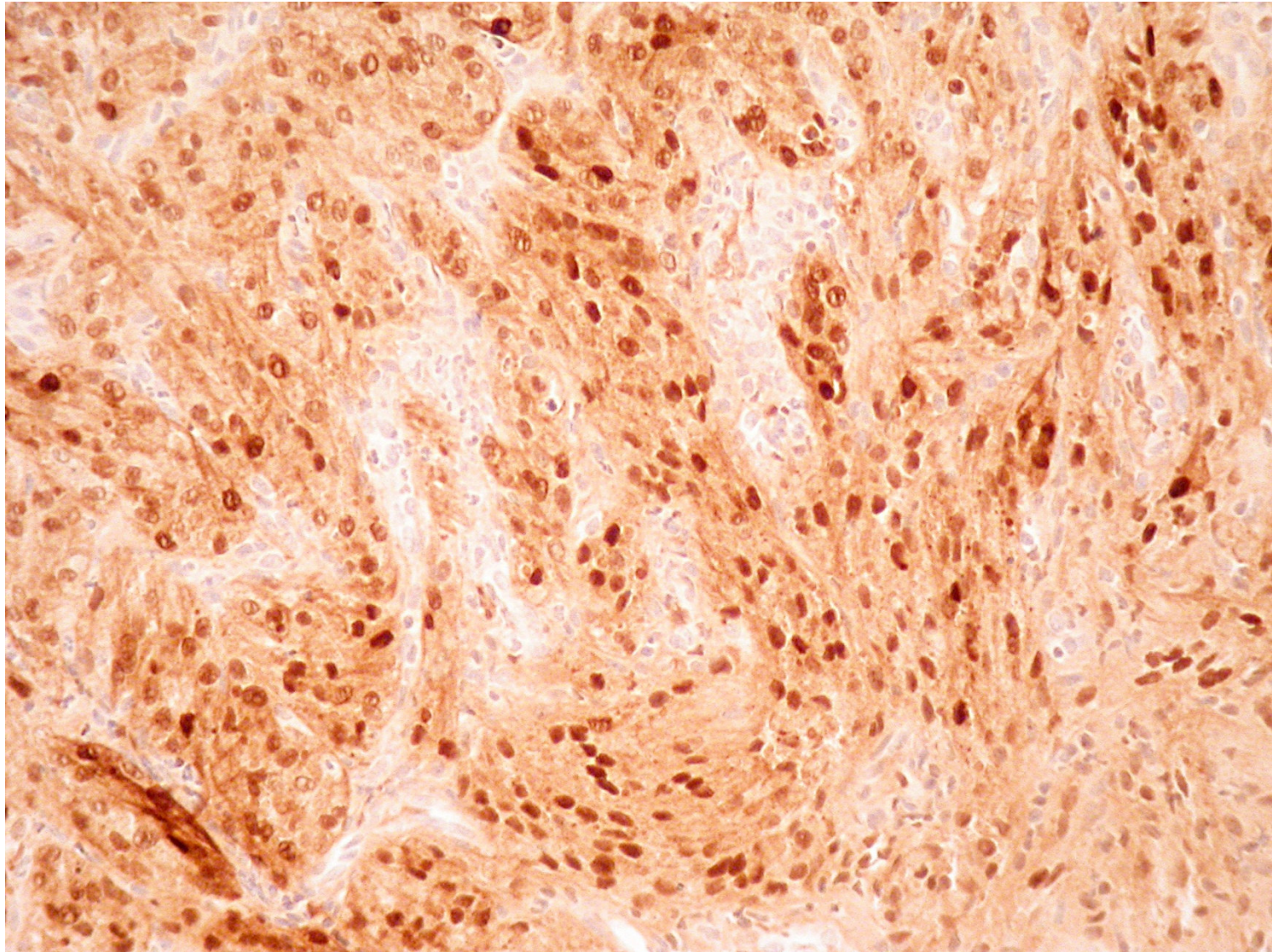
Slowly enlarging lesion left lateral border of tongue. Denture wearer



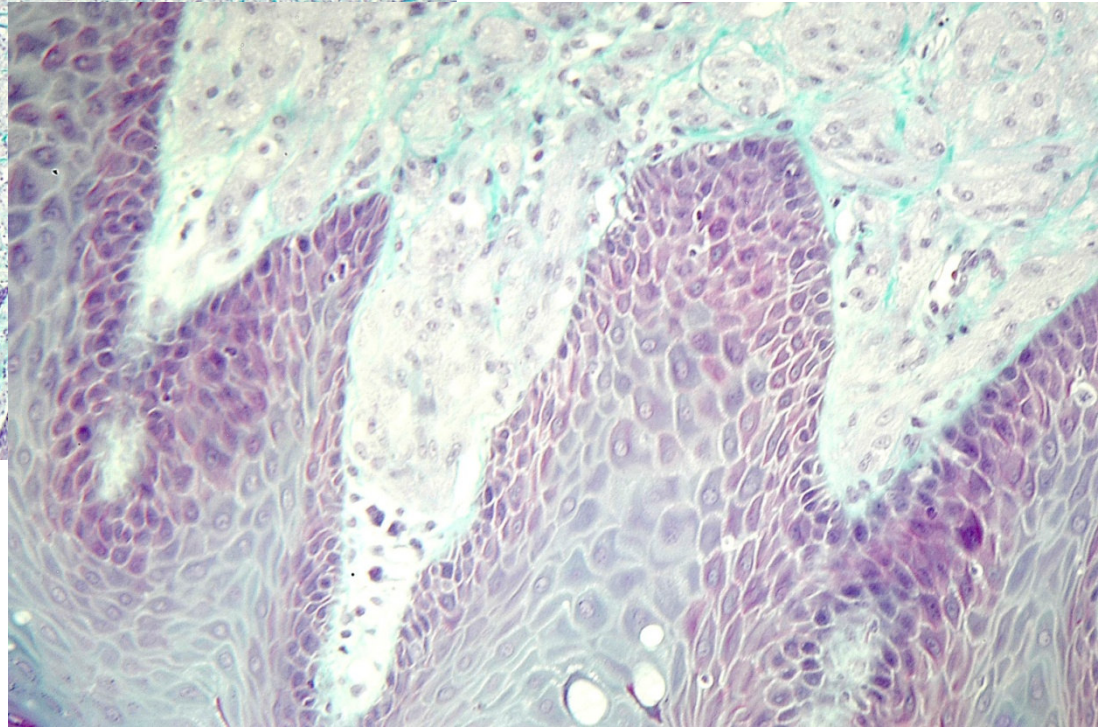
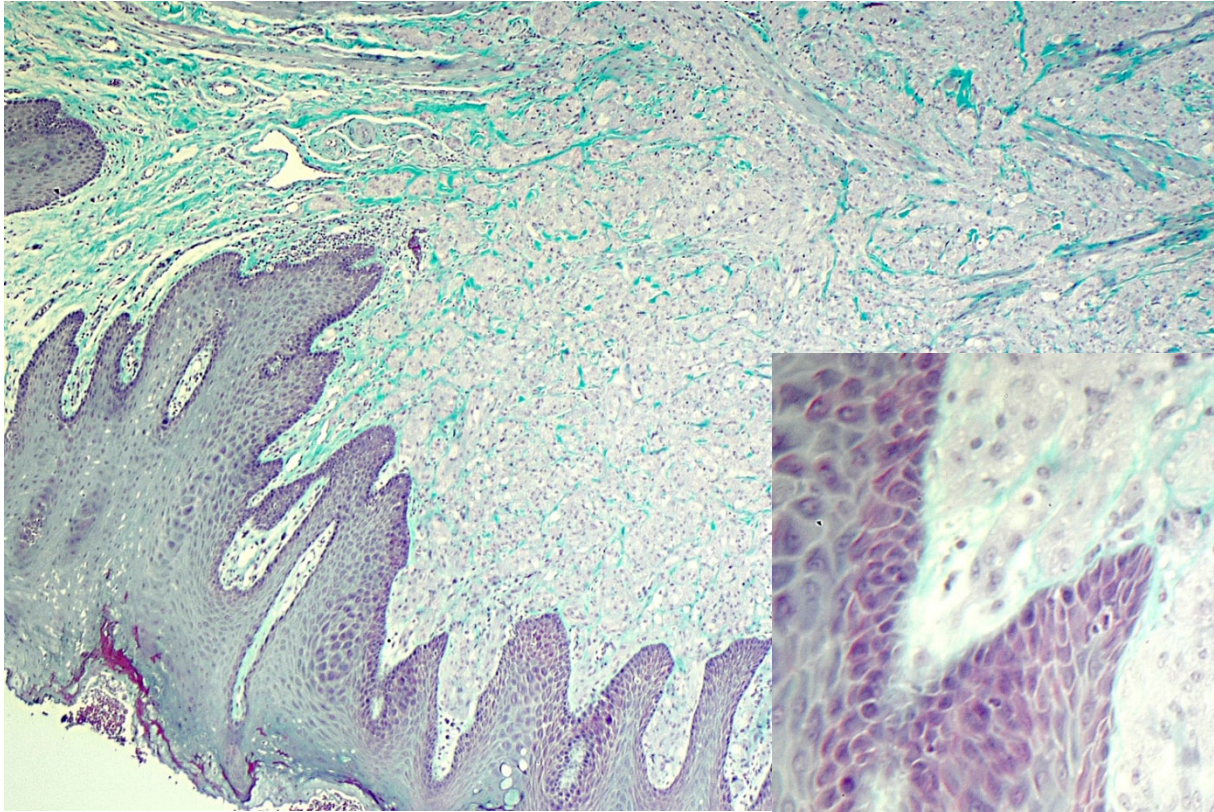
CK14



S100



S100



Masson trichrome